

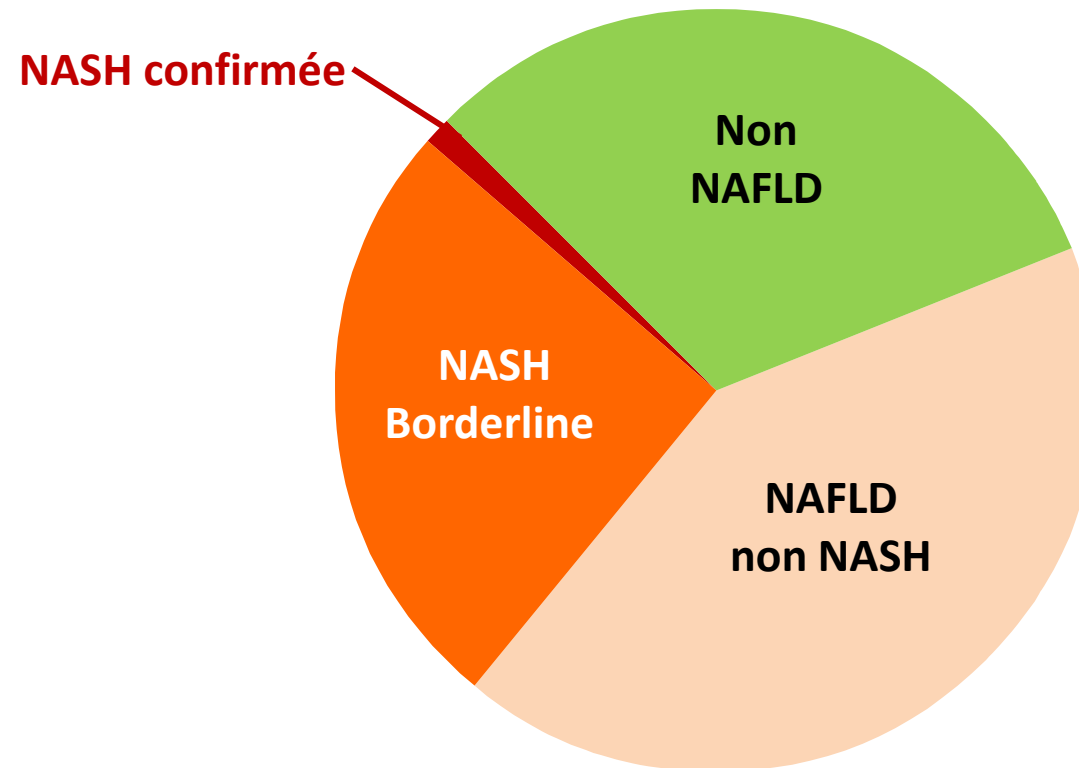


Adolescent obèse avec NAFLD : intérêt de la chirurgie

AASLD 2022 – Sundaram S et al. Abst. 234

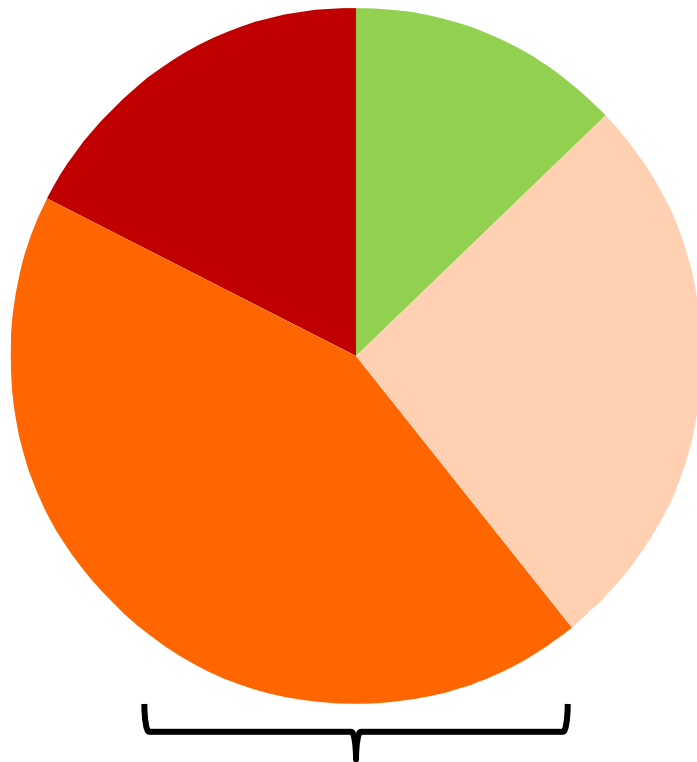
Histologie hépatique initiale (n= 101)

70,3 % NAFLD



Amélioration de l'histologie

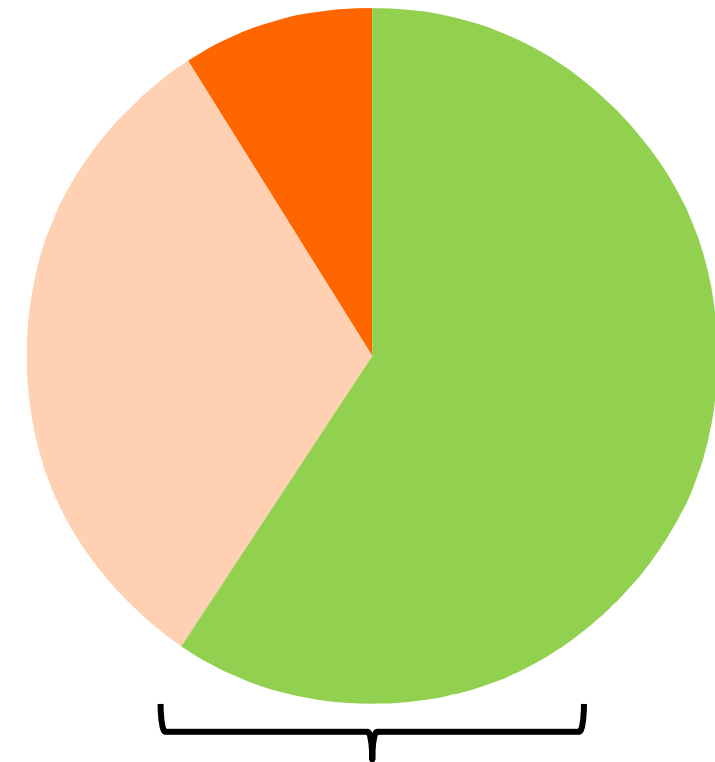
**Biopsie
initiale (n=23)**



87 % NAFLD

- Non NAFLD
- NAFLD non NASH
- Borderline NASH
- NASH confirmée

**Biopsie à 1 an
post-chir (n=23)**



40 % NAFLD